

Case Report

High mortality in geese associated with feeding tofu skin waste in Hebei Province, China

Xinwei Wang^{1,2*}, Chang Cai^{2,6}, Yin Li^{2,3}, Hao Tang^{2,4} and Ian D Robertson^{2,5}

¹College of Animal Science and Veterinary Medicine, Henan Agricultural University, No. 95 Wenhua Road, Zhengzhou City, Henan Province 450002, China

²School of Veterinary Medicine, Murdoch University, Murdoch 6150, Western Australia, Australia

³Department of Veterinary Epidemiology, China Animal Health and Epidemiology Centre, No. 369 Nanjing Road, Qingdao City, Shandong Province 266034, China

⁴FAO Emergency Center for Transboundary Animal Disease (ECTAD) China office of the United Nations, No. 14 Liangmahe Nan Road, Beijing City 100600, China

⁵China-Australia Joint Research and Training Center for Veterinary Epidemiology, College of Veterinary Medicine, Huazhong Agricultural University, No.1 Shizishan Road, Wuhan City, Hubei Province 430070, China

⁶China Australia Joint Laboratory for Animal Health Big Data Analytics, College of Animal Science and Technology, Zhejiang Agricultural and Forestry University, No. 88 Huanchengbei Road, Linan City, Zhejiang Province 311300, China

Received: 27 February, 2020

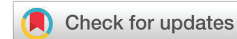Accepted: 04 March, 2020

Published: 02 April, 2020

***Corresponding author:** Xinwei Wang, College of Animal Science and Veterinary Medicine, Henan Agricultural University, No. 95 Wenhua Road, Zhengzhou City, Henan Province 450002, China, E-mail: xinweicliff@126.com

Keywords: Acute toxicity; Rongalite; Geese; Tofu waste

<https://www.peertechz.com>



Abstract

This case describes an unusual mortality in a flock of 4000 125-day-age geese fed with Tofu skin waste containing rongalite in a rural farm. Clinical symptoms, necropsy changes and intervention measures taken suggested poisoning of geese. Clinical investigation further confirmed that feeding Tofu skin waste was risk cause. This report is the first investigated case of feeding Tofu skin waste containing rongalite to lead geese to dead to date, having ruled out acutely contagious diseases with highly pathogenic avian influenza, gosling plague, goose paramyxovirus infection, and avian cholera, as well as poisoning due to the use of insecticide, anticoagulant rodenticides and heavy metals.

Introduction

Tofu skin waste is not expensive and reused as feed ingredients for animals because of its nutritional value. Tofu skin waste on the market is available and well qualified for animals. However, there may be unidentified tofu skin waste containing no clear and even illegal ingredients during its processing, such as the adoption of rongalite to process tofu skin, which will result in its waste containing prohibited ingredients, affecting the health of animals and humans.

In this study we report a case of goose poisoning caused by feeding tofu skin waste containing rongalite in a goose farm.

Case report

This case report describes mortalities in a flock of 4000 125-day-old geese after they were fed a ration containing up to 70% tofu skin waste in China. In June 2016 a goose farmer in Xingtai City, Hebei Province, China, introduced 4,102 60-day old goslings to his farm. These goslings were divided into



two groups: one for use as future breeders (1850); and one for growing out as meat birds (2252). The two groups were managed separately; however, both groups were allowed access to areas of pasture beneath walnut trees during the day. Both groups were fed a ration at 6pm each day consisting of equal parts of corn kernels and corn germ meal (a by-product after corn is pressed and its oil extracted). To control the body condition and weight of the goslings to be retained for breeding, the amount of feed given to these birds per head was approximately half (43%) that given to a meat gosling (ie for every kilogram of feed a breeder received a grower received 2.32 kg). Water for the two groups was obtained from the same pond.

On the 3rd August (120 days of age), there were approximately 1800 breeding geese and 2200 meat geese alive. Daily mortalities prior to this time had been ≤ 2 per day in total. On the 4th August, the residual waste from an enterprise making tofu skin sticks for human consumption was purchased from a seller and on that day was used to replace 10% of the total geese diet (ie 90% corn mix and 10% tofu skin waste). Tofu skin waste is a cheap protein supplement and is regularly fed at varying proportions to geese in China. On the 5th August, 13 geese (10 from the meat flock and 3 from the breeding flock) were observed to have died near the feeder (Table 1). Tofu skin waste was again incorporated into the diet (10%) and fed on the evening of the 5th August. On the 6th August a further 24 geese had died (Table 1). On the 6th August, due to a shortage of corn mix, the proportion of tofu skin waste was increased to 70% of the ration with the remaining 30% being corn mix. On the 7th August, 235 geese were found dead, with the majority (86.8%) being meat geese (Table 1). The deaths were reported to the Poultry Diseases Research Institute, Henan Agricultural University by the farmer on the following day (8th August 2016). On examination the majority of the flock was displaying some clinical signs including depression, weakness, reluctance to move, incoordination, head shaking, ruffled feathers and increased water consumption. On the advice of the veterinarians, tofu skin waste was removed from the ration and replaced with corn mix.

Autopsy and differential diagnosis

On necropsy the proventriculus and gizzard of three necropsied birds were found to be full of feed with sloughing

of the gizzard lining (Figure 1). The gastric mucosa was also easily peeled, the cecum and colon were full of white faeces that were not formed, and there was evidence of congestion and blackening of the liver (Figure 2). Liver and spleen samples were collected aseptically and subsequently cultured on sheep blood and MacConkey's agar and incubated aerobically at 37°C with 5% CO₂ for at least 24 hr. No pathogenic bacteria were cultured. Potential differential diagnoses for acute mortalities in geese include highly pathogenic avian influenza, gosling plague, goose paramyxovirus infection, and avian cholera, as well as poisoning due to the use of insecticide, anticoagulant rodenticides and heavy metals, although these had not been reported in the locality or province at the time of this outbreak.

Treatment

Based on the clinical characteristics, the veterinarians from the Institutemade made a preliminary diagnosis of food poisoning and immediately suggested measures were taken for geese: Electrolyte multivitamins (Grosol plus, Bayer (Si chuan) Animal Health Co. Ltd.) at 1g per 2 l of water along with 5% glucose (Edible glucose, Shandong Xiwang glucose Co. Ltd.) was added into the feed on the 8th and 9th August. 5% glucose and electrolyte multivitamins (Grosol plus) at 1g per 4 L water were provided for a further two days (10th and 11th August).

Outcome and follow up

Epidemiology diagnosis: Daily telephone checks with the farmer were conducted by the veterinarians from the Institute until the 11th August. The follow up showed that clinical intervention measures taken were effective and the flock of geese recovered on the 11th August.

Data on the mortalities and the association with feed, groups and days were analyzed by calculating relative risks and their 95% confidence intervals (95%CI) and chi-square tests for independence. A Pearson's correlation coefficient between the percentage of tofu waste in the diet and mortality was also calculated.

Birds in the meat flock (which consumed, on average, 2.32 times the amount of feed per head of a breeder) were 4.84 (95%CI: 3.70–6.33) times more likely to have died than geese in the breeding flock ($P < 0.0001$).

Table 1: Number of dead geese and their ration and treatment during the outbreak.

Date (August)	Number of live geese			Number of deaths						Total
	3 rd	4 th	5 th	6 th	7 th	8 th	9 th	10 th	11 th	
Meat geese	2200	0	10	17	204	109	8	1	0	349
Breeding geese	1800	1	3	7	31	13	3	1	0	59
Total number of deaths	0	1	13	24	235	122	11	2	0	408
Overall mortality (%)	0	0.03	0.33	0.6	5.93	3.27	0.31	0.06	0.0	
Relative risk for death (95%CI)	-	1.0	13 (1.7, 99.4)	24.1 (3.3, 177.9)	237.3 (33.3, 1690.5)	130.9 (18.3, 936.6)	12.2 (1.6, 94.5)	2.2 (0.2, 24.5)	-	
Ration* (%)	Corn	50	40	40	0	50	50	50	50	50
	Corn germ#	50	50	50	30	50	50	50	50	50
	Tofu skin waste	0	10	10	70	0	0	0	0	0

By-product from corn after pressing for extracting the oil.

* An individual breeding goose received, on average, 43% of that fed to a meat goose.

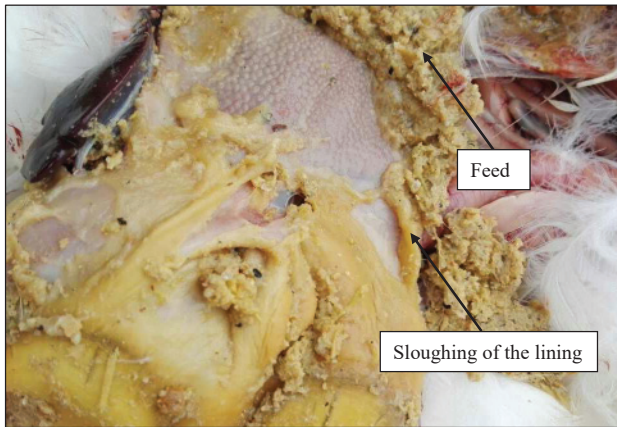


Figure 1: Sloughing of the lining between proventriculus and gizzard.

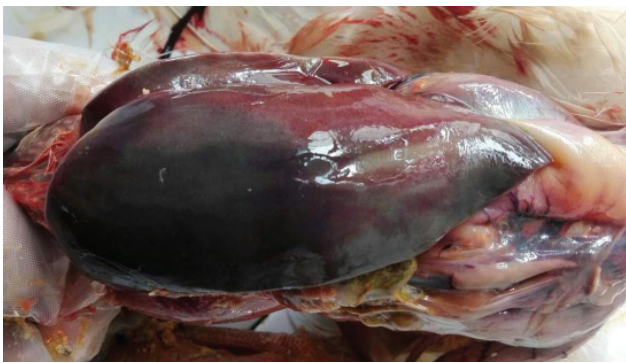

Figure 2: Hepatic congestion with black discoloration.

The day after the birds were fed a ration containing 70% tofu skin waste, mortalities increased significantly (RR 237.3; 95%CI 33.3–1690.5) compared with when no tofu skin waste was fed (4th August) (Table 1). There was a strong correlation between the number of dead geese and the percentage of tofu skin waste fed in the previous evening ($r=0.85$, $p<0.02$). The above clinical comprehensive diagnosis results indicated that tofu skin waste was the real dangerous cause of goose poisoning.

Discussion

In this case, autopsy clearly showed that the dead goose's glandular and muscular stomachs were filled with feed, the cecum and colon full of unformed white feces, the liver swollen and congested with black discoloration, as well as no symptomatic changes of any acute infectious diseases appeared. These clinicopathological anatomical changes suggested that geese died of acute death. On clinical epidemiological investigations, as the management, environment, drinking water and feeding style, other than the amount of ration provided, were similar for the breeding and meat geese, and deaths had been consistently low prior to the ration change (significant correlation between the number of dead geese and the percentage of tofu skin waste fed ($r=0.85$, $p<0.02$)), together with the effect of clinical intervention, the above findings logically supported a diagnosis of acute poisoning associated with the consumption of this specific batch of waste tofu. Unfortunately no tofu waste was available for toxicological analysis; however tofu

waste (although not this batch) had been widely used by other geese farmers with no prior reports of high level mortalities or morbidities in China. This geese farmer had previously fed tofu waste at a low proportion (<10%) with no deleterious effects. Confusingly and interestingly, information by telephone follow up showed that the farmer had known that the tofu skin waste he bought contained rongalite, and also provided valuable clinical evidence: based on previous feeding experience, the farmer subjectively believed that feeding tofu skin waste to his geese was not a problem. Thus, in the absence of other feeds, the farmer incorrectly fed the geese large doses of tofu skin waste. This eventually caused goose poisoning, which also suggested that there may be cases where individual farmers violated animal welfare principles and used illegal feed to raise animals.

Rongalite® (BASF) or (Bruggolite®, INCI) (active ingredient of sodium hydroxymethyl sulfinate ($\text{Na}^+\text{HOCH}_2\text{SO}_2^-$), which is also known as sodium formaldehyde sulfoxylate or sodium oxymethylene sulfoxylate) [1] is widely used as an industrial bleaching agent in the printing and dyeing industries [2,3]. As it is suspected to be carcinogenic, its addition to human and animal feed has been banned in many countries, including China [4]. However, recently it has been detected in soya bean products (rolled dried soya bean cream also known as tofu skin sticks), wheat flour products (steamed bread) and rice products (rice vermicelli) in China [5]. The preference of consumers for whiter, chewy tofu skin sticks with a long shelf life encourages the illegal use of rongalite as a food additive [5,6]. Although its legal manufacture has been restricted to four chemical plants in China and a sales register established, some illegal manufacture has been reported for use in human food products [7]. This case is to some extent another evidence (illegal use of rongalite to produce Tofu skin) and also special food poisoning for geese. The acute toxicity demonstrated in this study after feeding tofu skin waste strongly suggests formaldehyde toxicity as a result of the breakdown of rongalite *in vivo* and highlights the potential toxicity of rongalite in geese. And that has enriched the clinical data of the potential toxicity of rongalite, but the mechanism of its toxicity needs further to be researched and analyzed.

Conclusion

This case not only described high mortality in geese associated with feeding tofu skin waste containing rongalite, but also highlights the dangers arising from purchasing feed of an unknown status from an unlicensed supplier, as well as highlights demand for more information surrounding the subject to be made available to the veterinarian.

Acknowledgements

This work was supported by the China Scholarship Council under Grant No. 201508410377, while the lead author was a visiting scholar at Murdoch University.

References

- Lewis RJ (2000) Sax's Dangerous Properties of Industrial Materials. 10th ed. Volumes 2-3. New York, JOHN WILEY & SONS, INC. 1824-1825,3249-3250. [Link: Link: https://bit.ly/3aBQhJb](https://bit.ly/3aBQhJb)



2. Owen S (2013) Material Safety Data Sheet. In S.C.M. Corp (Ed.). The USA.
3. Schubart R (2000) Sulfinic Acids and Derivatives. In Ullmann's Encyclopedia of Industrial Chemistry: Wiley-VCH Verlag GmbH & Co. KGaA. [Link: https://bit.ly/2X0sPS1](https://bit.ly/2X0sPS1)
4. Du W (2012) Current criminal law of food safety and its improvement. In School of Law. 120.
5. Feng J (2011) Hazards and detecting methods for sodium formaldehyde sulfoxylate in food. Storage and Process 11: 5. [Link: https://bit.ly/3aBQhJb](https://bit.ly/3aBQhJb)
6. Wu L (2010) Analysis of illegal food additives--rongalite. Science & Technology Association Forum. 8: 3.
7. Sun X (2003) Rongalite has been controlled from the source. In. China: Automotive Quality.

Discover a bigger Impact and Visibility of your article publication with Peertechz Publications

Highlights

- ❖ Signatory publisher of ORCID
- ❖ Signatory Publisher of DORA (San Francisco Declaration on Research Assessment)
- ❖ Articles archived in worlds' renowned service providers such as Portico, CNKI, AGRIS, TDNet, Base (Bielefeld University Library), CrossRef, Scilit, J-Gate etc.
- ❖ Journals indexed in ICMJE, SHERPA/ROMEO, Google Scholar etc.
- ❖ OAI-PMH (Open Archives Initiative Protocol for Metadata Harvesting)
- ❖ Dedicated Editorial Board for every journal
- ❖ Accurate and rapid peer-review process
- ❖ Increased citations of published articles through promotions
- ❖ Reduced timeline for article publication

Submit your articles and experience a new surge in publication services
(<https://www.peertechz.com/submission>).

Peertechz journals wishes everlasting success in your every endeavours.

Copyright: © 2020 Wang X, et al. This is an open-access article distributed under the terms of the Creative Commons Attribution License, which permits unrestricted use, distribution, and reproduction in any medium, provided the original author and source are credited.